

Evaluation of Clinical Algorithm in Acute Appendicitis with the Aim to Reduce the Negative Appendectomy Rate

Dr. Paras Batra¹, Dr. Shrikant Kurhade², Dr. (Brig.) K.V.S Rana³,
Dr. Abhishek Singh⁴, Dr. Aditi Zaveri⁵, Dr. Jushmita Pathak⁶

^{1,2,3,4} Department Of General Surgery, Dr. D.Y. Patil Medical College, Hospital And Research Centre, Pimpri, Pune, India

^{5,6} Dr. D.Y. Patil Medical College, Hospital And Research Centre, Pimpri, Pune, India

Abstract: The diagnosis of acute appendicitis has always been clinical but associated with a high negative appendectomy rate (NAR). Clinical scoring systems such as RIPASA score and ALVARADO score, USG, CT scan and diagnostic laparoscopy have been used in the past as modalities for diagnosis. They have been used as separate modalities but never in adjunct to each other. So these modalities were used in an algorithm together to decrease the NAR without increasing the rate of complications.

100 cases of pain in right iliac fossa, which were operated for acute appendicitis were included in the study. The mean age was 27.62±8.43 years. The use of RIPASA score and USG as adjunct was able to diagnose 94% of the cases with only 1 negative appendectomy. The sensitivity was 95.88% with 66.67% specificity and PPV of 98.94%. Using all these modalities the NAR was brought down to 3% with an acceptable rate of complications i.e. 13%.

RIPASA Scoring system and USG in adjunct have very high diagnostic accuracy. The cut-off value of RIPASA can be kept as 10 as we found in our study that those with score of 10-11.5 had suppurative appendicitis in 85% of the cases.

Keywords: acute appendicitis, NAR, RIPASA

I. Introduction

Acute appendicitis is defined as the presence of transmural inflammation or pus in the lumen of the appendix. [1] It has a lifetime incidence of 7-10%. Acute appendicitis, along with its protean manifestations, can mimic almost any acute abdominal illness and in turn can be mimicked by any one of them. It is thus necessary to make an accurate diagnosis so that unnecessary surgery isn't performed. The dilemma doesn't end there; situations also occur wherein if we don't act in a precise and systematic manner, this vicious disease could result in a high morbidity and mortality. [2]

The Alvarado score, modified Alvarado score and the RIPASA score are the various scoring systems that are usually consulted. [3,7] In many patients, the presence of certain signs and symptoms is very helpful in confirming appendicitis, but conversely, the absence of these signs and symptoms does not rule out a diagnosis of appendicitis. [4]

Pain migration from umbilicus to right lower quadrant in adults is the best indicator of appendicitis, while the absence of pain prior to vomiting almost always rules it out. The picture in children is quite variegated; though the presence of vomiting, rectal tenderness, rebound tenderness and fever in this age group is considered extremely relevant. Diarrhea may also be a presenting symptom of acute appendicitis depending on the position of the vermiform appendix. [5]

Negative appendectomy rate (NAR) is defined as the rate of surgically removed appendixes that are pathologically normal. [6,7,8] It varies from 15 to 25% [9] and is found to be higher in women than men, in whom making a diagnosis of acute appendicitis even more difficult. [10,11]

Various modalities such as a clinical examination, ultrasonography, CT scan and diagnostic laparoscopy are used to diagnose acute appendicitis. While these diagnostic tools have been studied separately, it is hypothesized that use of all these modalities together within a single clinical algorithm will help reduce the Negative Appendectomy Rate without increasing the rate of complications.

II. Aims And Objectives

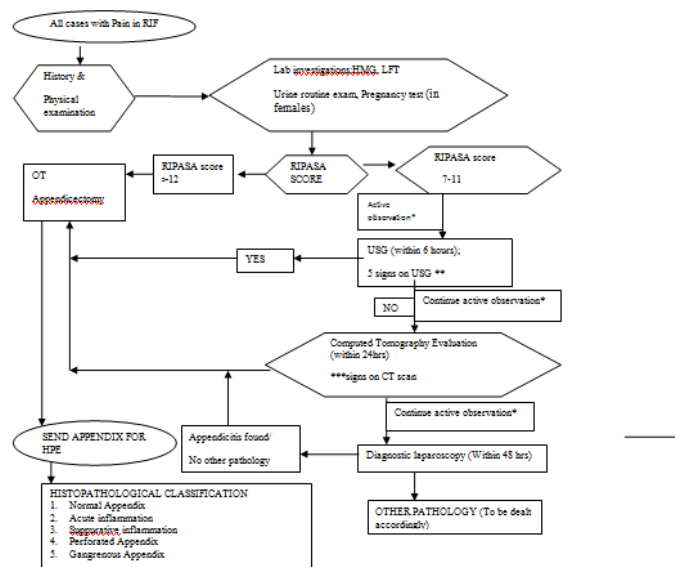
2.1 Aims:

2.1.1 To evaluate a clinical algorithm in acute appendicitis with the aim to decrease the Negative Appendectomy Rate by using RIPASA score, USG, CT evaluation and diagnostic laparoscopy without increasing the rate of complications.

2.2 Objectives:

- 2.2.1 To evaluate the role of clinical diagnosis using RIPASA SCORE in decreasing the negative appendectomy rate
- 2.2.2 To evaluate the role of clinical diagnosis and ultrasonographic diagnosis in decreasing the negative appendectomy rate
- 2.2.3 To evaluate the role of clinical diagnosis, ultrasonographic diagnosis and CT evaluation in decreasing the negative appendectomy rate
- 2.2.4 To evaluate the role all these and diagnostic laparoscopy in decreasing the negative appendectomy rate.
- 2.2.5 To evaluate all these modalities for their specificities and sensitivities, Positive predictive value (PPV) & Negative predictive value (NPV).

1. The Clinical Algorithm



* Active observation- IV fluids and analgesics and 2 hourly RIPASA score monitoring. If RIPASA score becomes ≥ 12 during active observation, patient will be taken for surgery.

** 5 signs on USG-

- A. dilated appendix outer diameter $> 6\text{mm}$
- B. noncompressible
- C. distinct appendiceal wall layers due to oedema
- D. target appearance (axial section)
- E. appendicolith- an echogenic focus with posterior shadowing

*** Signs of appendicitis on CT scan include

- A. Visualization of appendiceal enlargement (greater than 6 mm in cross-sectional diameter)
- B. lack of oral contrast (oral dye) in the appendix
- C. direct and appendiceal wall enhancement with IV contrast (IV dye)

III. Materials

4.1 Inclusion Criteria: One hundred patients admitted into the institution with right iliac fossa (RIF) pain, above the age of 5 years, who underwent emergency appendectomies for the same, were included in the study.

4.2 Exclusion Criteria: Patients who were discharged after conservative management were excluded from the study.

4.3 Plan of Study:

4.3.1 All patients with pain in the RIF were admitted. A detailed patient history was taken and a physical examination done. All the routine investigations mentioned in the above algorithm were sent.

4.3.2 All the included patients were kept nil orally. I.V fluids and analgesics (Inj. Voveron 75mg 8 hourly IV and Inj. Tramadol 100mg in 100ml NS IV HS) were given (active observation). Each patient's RIPASA score was calculated.

4.3.3 If the RIPASA Score was > 12 , the patient was taken to the OT and an appendectomy was done after starting the first dose of IV antibiotics (Inj. Cefotaxim 12 hourly and Inj. Metronidazole 8 hourly).

4.3.4 If the RIPASA Score was between 7 and 11, the patient was actively observed and the RIPASA score of monitored in 2 hourly intervals. A USG was then done within 6 hours. If hard signs of appendicitis were present on the USG, the patient was taken to the OT for an appendectomy after starting the first dose of IV antibiotics. If no signs of appendicitis were seen on the USG, and the score was still 7-11, the patient was continued to be actively observed.

4.3.5 A CT scan was performed within the next 24 hours. If the patient was found to be positive for appendicitis on CT, they were taken to the OT for an appendectomy, after starting them on IV antibiotics. In the absence of any signs of appendicitis on CT, and the RIPASA score was still 7-11, the patient was continued to be actively observed. Other pathologies found on the CT scan in these patients were managed accordingly.

4.3.6 If pain in the RIF still persisted and RIPASA score still 7-11, a diagnostic laparoscopy was done within 48 hours. If appendicitis was found on laparoscopy, the appendix was removed. Other pathologies found on laparoscopy were managed accordingly. However if no other pathology found, appendix was still removed laparoscopically.

4.3.7 All removed appendixes were sent for HPE and histopathology was analysed as follows

- a) Normal appendix
- b) Acute appendicitis
 - c) Suppurative appendicitis
 - d) Perforated appendicitis
 - e) Gangrenous appendicitis

4.3.8 Perforated appendicitis and gangrenous appendicitis were considered complications of acute appendicitis.

4.3.9 The patients were observed post-operatively for any complications. If no complications followed, the sutures were removed and patient was discharged on the 7th post-operative day.

4.3.10 If the RIPASA score was <5 , the patient was actively observed for 24 hours. If it still remained <5 , the patient was discharged after being monitored for 48-72 hours. All the data was collected and statistically analyzed using the Chi-square and Mann Whitney tests as applicable using SPSS (Version 17) to calculate the overall sensitivities, specificities, NPV and PPV required for the purposes of this study.

IV. Results

Out of the 100 cases, in the 14 cases where the RIPASA score was ≥ 12 , the score was used as the only diagnostic criteria for acute appendicitis. The RIPASA score was 100% accurate in the diagnosis of acute appendicitis in these cases, but was consequently complicated. In the remaining 86 patients where the RIPASA score stood between 7 and 11, USH was performed within 6 hours. Out of these, 80 cases were showed signs of acute appendicitis on USG and were subsequently operated upon. Of these, there was only 1 negative appendectomy and 1 complicated appendicitis. The remaining 6 cases with a RIPASA score between 7-11 and a negative USG were later taken up for a CT scan. 4 cases showed positive hard signs of acute appendicitis on CT scan, and out of these four, two were reported as a negative appendectomy. The remaining two cases with a RIPASA score between 7 and 1, negative USG and negative CT scan but with complains of RIF pain were subjected to a diagnostic laparoscopy. Appendectomies were done in both cases were both were histopathologically found to be acute appendicitis.

V. Discussion

The age-wise distribution among this study group showed 43 cases of appendicitis within the age group of 21 to 30 years, followed by 23 cases within the age group of 11 to 20 yrs. Thirteen cases were within age group of 31 to 40 yrs. As the patient's age advanced, the number of cases of appendicitis encountered in our study decreased, with only 15 cases encountered within the age group of 41 yrs and above. Thus, 85% of the patients were below the age of 40 years, and 15% fell above the age of 40 years (Table 1). The mean age was 27.69 ± 8.43 years (range 6-64 years). Similar findings were observed in a study conducted by Marwah Karan et al (2015), who studied the significance of RIPASA Scoring System in the diagnosis of Acute Appendicitis. The age distribution among cases showed 80% of patients below the age of 40 years, with 20% cases above the age of 40 years. [12]

Majority of cases were males as compared to females for appendicitis in the study. 59% were males and 41% were females. In the study by Hasan Erdem et al. (2013), out of the 113 patients with suspected acute appendicitis included, 62 were males and 51 females. [13]

The RIPASA score was greater than or equal to 12 in 14 cases and less than 12 in the remaining 86 cases (Table 2). Out of the 14 cases with a RIPASA score ≥ 12 , twelve cases presented with perforated/gangrenous appendicitis. Of the remaining two cases from the 14 with a RIPASA score ≥ 12 , one was found to be acute suppurative appendicitis and the other, acute appendicitis on HPE. Thus, the probability of gangrenous/perforated appendicitis was very high with a RIPASA score ≥ 12 . Similar findings were also

observed in a study conducted by Wen Liu, Jin Wei Qiang and RongXun Sun (2014), who compared the RIPASA and Alvarado scores with multi slice computed tomography (MSCT) for diagnosing acute appendicitis (AA). The mean RIPASA score was 11 in the Simple Acute Appendicitis group compared with other forms of Acute Appendicitis such as perforated appendicitis, gangrenous appendicitis etc., which had a score of more than 12. [14] Similar findings were observed in the previously mentioned study by Marwah Karan et al., who concluded that there is high possibility of finding a gangrenous appendix when the RIPASA score exceeded 12.[12]

In our study 86 cases who had RIPASA score <12 were subjected to USG. The USG findings showed an increased diameter of more than 6mm in 67 cases, a target sign in 63 cases, non-compressible appendixes in 41 cases, and wall layer edema in 12 cases. Appendicoliths were seen in 30 patients. The 80 cases with positive findings on USG then underwent surgery, and of them 78 proved to have acute appendicitis on HPE, with 1 case of complicated appendicitis and 1 case found be normal on HPE. A sensitivity of 95.88% and specificity of 66.67% was observed. The positive predictive value and negative predictive value for detecting acute appendicitis in cases with both a RIPASA score ≥ 12 and positive USG findings were 98.94% and 33.33% respectively. Similar finding were seen in a study conducted by SacharSudhir, (2013) the main USG features for diagnosing acute appendicitis were an incompressible appendix with a transverse outer diameter of >7 within compressible periappendicular inflamed fat with or without an appendicolith.[15]

The association between combining a RIPASA score and USG with HPE was significant for detecting acute appendicitis. Among 94 cases with positive finding on RIPASA and USG, 93 cases were detected to be acute appendicitis by histopathological examination. The combination of RIPASA and USG method was 95.88% sensitive for detecting acute appendicitis and 66.67% specific. Positive predictive value was 98.94% for the combination (Table 4). In a study by Mardan MA, Mufti TS, Khattak IU, Chilkunda N et al (2007) assessing the role of this diagnostic modality USG in the management of acute appendicitis, results showed that the addition of routine ultrasonography in clinical assessment for acute appendicitis decreases the sensitivity but significantly increases the specificity of the protocol thereby reducing the false positive rate translating into decreased negative appendectomy rate.[16] In our study negative appendectomy rate was 3%, which is comparable to the aforementioned study's 4.7%.

The association between combining RIPASA score with both USG and CT and finally assessed on HPE was statistically significant for detecting acute appendicitis. Among 98 cases with positive findings on RIPASA+USG+CT, 95 cases were detected as acute appendicitis on histopathology. The combination of these three methods was 98.97% sensitive for detecting acute appendicitis. The positive predictive value was 97.96% i.e. detecting acute appendicitis using these three methods is highly effective (Table 5). Giuseppe D'Ippolito, Giselle GuedesNetto de Mello, JacobSzejnfeld (1998) established the accuracy of unenhanced CT in the preoperative diagnosis of acute appendicitis. Acute appendicitis was confirmed in 44 cases using CT scan. Sensitivity was 91% and positive predictive value was 100%. In our study sensitivity was 98.97% and positive predictive value was 97.96%. [17]

The association between combining RIPASA score plus USG plus CT and Diagnostic laparoscopy with HPE was not statistically significant for detecting acute appendicitis. Among 100 cases with positive finding on RIPASA+USG+CT+DL, 97 cases were detected as acute appendicitis on HPE method. Combination of four methods was 98.91% sensitive for detecting acute appendicitis. Positive predictive value was 98.91% i.e. detecting acute appendicitis with using four methods is highly useful before doing HPE. (Table no 6). Wim T. Van Den Broek, Bart B. Bijnen, Bram Rijbroek and Dirk J. Gouma (2002) developed a reproducible scoring system to identify patients who present with a doubtful diagnosis of appendicitis and who would benefit from diagnostic laparoscopy. Results showed a sensitivity of 93% and a specificity of 83% it suggests good accuracy. The normal appendectomy rate would be 7% instead of 9%, and the negative exploration rates would both be 22%. In the present study sensitivity and positive predictive value both were 98.91% respectively that proves good accuracy for detecting acute appendectomy on laparoscopy when other modalities were used along with it. [18]HPE diagnosis of cases showed that 84% had acute appendicitis, 8% had perforated appendixes, 5% had gangrenous appendix and only 3% had normal (Table 3). Similar finding was observed in a study conducted by HasanErdem et al (2013) assessing the reliability and practical applicability of the widely used RIPASA scoring systems in patients with suspected acute appendicitis. One hundred and thirteen patients with suspected acute appendicitis were included in the study. Of the 113 patients, 94 patients underwent surgery, while the rest were followed non-operatively. Of the 94 patients, 77 patients were histopathologically diagnosed with acute appendicitis and 17 were normal on HPE.[13]

In the present study, NAR came out to be 3% (Table 7). Similar findings were observed in a study by Subedi N, Dangol US, Adhikary MB, Pudasaini S, Baral R (2011) analyzed clinical presentation of acute appendicitis and its histopathological correlation. Out of the 345 patients who underwent operative procedure, 98% (n= 338) came with chief complaints of pain in the periumbilical region migrating to the right iliac fossa. The most common perioperative finding was acutely inflamed appendix (84%) followed by perforated

appendix (7.5%), gangrenous appendix (3.5%) and appendicular lump (1.5%). However, histopathological diagnoses were acute appendicitis (91.9%), resolving appendicitis (3.5%), lymphoid hyperplasia (2.6%), mucocele (0.3%) and carcinoid (0.3%). Normal histology was seen in 1.4% cases.[19]

VI. Conclusion

Clinical examination with RIPASA score ≥ 12 when only the score was used for diagnosis, we were able to diagnose 100% cases on HPE but the rate of complications was as high as 86% in this group. In the cases with RIPASA score 10-11.5, most of the cases were suppurative appendicitis and a few normal appendixes. Complications were present only in 1 case. Here USG with the classical 5 signs was used as adjunct for diagnosis of acute appendicitis. We were able to diagnose 94% of the cases with the use of just RIPASA score and USG with only 1 negative appendectomy. These two modalities together had a high specificity and sensitivity and a high PPV. In the 6 cases where CT scan was used, in 4 cases we were able to diagnose but it was a normal appendix in 2 cases. So, only cross sectional diameter $>6\text{mm}$ was a reliable indicator for acute appendicitis if we went according to our algorithm. Diagnostic laparoscopy was used in 2 cases, both of them were acute appendicitis on HPE. A NAR of 3% was achieved using clinical examination using RIPASA score and all these diagnostic tools with decrease in the acceptable rate of complications. The rate of complications was 13% only. The cut-off value of RIPASA can be kept as 10 as we found in our study that those with score 10-11.5 had mostly suppurative appendicitis. So, by evaluating this clinical algorithm we were able to reduce the NAR without increasing the rate of complications.

VII. Tables

Table 1: Age wise distribution of cases in study group

Age (Yrs)	No of cases	Percentage %
<10	6	6
11 – 20	23	23
21 – 30	43	43
31 – 40	13	13
41 – 50	6	6
>50	9	9
Total	100	100

Table 2: RIPASA score of cases in study group

RIPASA score	No of cases	Percentage
≥ 12	14	14
<12	86	86
Total	100	100

Table 3: HPE findings in study group

HPE	No of cases	Percentage
Acute appendicitis	71	71
Suppurative appendicitis	13	13
Perforated appendicitis	8	8
Gangrenous appendicitis	5	5
Normal appendix	3	3
Total	100	100

Table 4: Association between RIPASA score + USG and HPE in cases group

	HPE		Total
	Acute appendicitis	Normal appendix	
RIPASA score $\geq 12+$ positive USG	93	1	94
Negative USG and RIPASA <12	4	2	6
Total	97	3	100

Fisher exact test = 0.001 Sensitivity = 95.88% Specificity = 66.67%
 PPV = 98.94% NPV = 33.33%

Table 5: Association between RIPASA score + USG +CT with HPE findings

	HPE		Total
	Acute appendicitis	Normal appendix	
RIPASA score ≥ 12 and positive USG and/or CT	95	3	98
Negative CT	2	0	2
Total	97	3	100

Fisher exact test = 0.01 Sensitivity = 98.97% Specificity = 33.33%
 PPV = 97.96% NPV = 50%

Table 6: Association between RIPASA score +USG+CT+ LAPAROSCOPY and appendectomy in cases group

	HPE		Total
	Acute	Normal	
RIPASA score +USG + CT+DL Positive	97	3	100
Total	97	3	100

Fisher exact test = 0.01 Sensitivity = 98.91% Specificity = 0%
 PPV = 98.91% NPV = 0%

Table 7: Association between RIPASA score and HPE in cases group

HPE	RIPASA score		Total
	≥ 12	< 12	
Acute	1	70	71
Suppurative	1	12	13
Perforated	7	1	8
Gangrenous	5	0	5
Normal	0	3	3
Total	14	86	100

References

- [1]. Beasley SW. Can we improve diagnosis of acute appendicitis? *BMJ* 2000;321:907-10.
- [2]. Flum DR, McClure TD, Morris A, Koepsell T. Misdiagnosis of appendicitis and the use of diagnostic imaging. *J Am Coll Surg* 2005; 201: 933–939.
- [3]. Wani MM, Yousaf MN, Khan MA, et al. Usefulness of the Alvarado scoring system with respect to age, sex and time of presentation, with regression analysis of individual parameters. *Internet J Surg* 2007; 11(2).
- [4]. Temple CL, Huchcroft SA, Temple WJ. The natural history of appendicitis in adults: a prospective study. *Ann Surg.* 1995;221:278–81.
- [5]. Bundy DG, Byerley JS, Liles EA, Perrin EM, Katznelson J, Rice HE. Does this child have appendicitis? *JAMA.* 2007;298(4):438–451.
- [6]. Randal Bollinger et al. (2007) Randal Bollinger R, Barbas AS, Bush EL, Lin SS, Parker W. Biofilms in the large bowel suggest an apparent function of the human vermiform appendix. *Journal of Theoretical Biology.*2007;249:826–831. doi: 10.1016/j.jtbi.2007.08.032.
- [7]. Chong CF, Adi MI, Thien A, et al. Development of the RIPASA score: a new appendicitis scoring system for the diagnosis of acute appendicitis. *Singapore Med J* 2010; 51:220-25.
- [8]. Velanovich V , Satava R . Balancing the normal appendectomy rate with the perforated appendicitis rate: implications for quality assurance. *Am Surg* 1992 ; 58 (4) : 264 – 69
- [9]. Detmer DE , Nevers LE , Sikes ED Jr . Regional results of acute appendicitis care .*JAMA* 1981 ; 246 (12) : 1318 – 20 .
- [10]. Antevil J , Rivera L , Langenberg B , Brown CV . The influence of age and gender on the utility of computed tomography to diagnose acute appendicitis . *Am Surg* 2004 ;70 (10) : 850 – 53
- [11]. Körner H , Söndena K , Söreide JA , et al . Incidence of acute nonperforated and perforated appendicitis: age-specific and sex-specific analysis. *World J Surg* 1997; 21 (3): 313 – 317
- [12]. Marwah Karan, Maheshwari Kumar Mukesh, Krishna Atul, Agarwal Vijay, Kumar Deepak, Jain Atul, Prasad Akshay. Significance of Ripasa Scoring System in Diagnosis of Acute Appendicitis. *International Journal of Healthcare Sciences* 2015; Vol. 3, Issue 1 4-10)
- [13]. Erdem H, Çetinküner S, Daş K, Reyhan E, Değer C, Aziret M et al. Alvarado, Eskelinen, Ohmann and Raja Isteri/Pengiran Anak Saleha Appendicitis scores for diagnosis of acute appendicitis. *World J Gastroenterol.* 2013;19(47):9057-62
- [14]. Wen Liu et al. Comparison of multislice computed tomography and clinical scores for diagnosing acute appendicitis. *Journal of International Medical Research* 2014;0(0):1–9
- [15]. SacharSudhir, MaheshwariAlok, BalianSubhash, Goyal Sunder, SacharSaurabh, GoyalSnigdha. Comparative study Of ultrasonography (USG) Versus Computed Tomography (CT) In Clinically Suspected Cases Of Acute Appendicitis: Retrospective study Of 100 cases. *Journal of Advance Researches in Biological Sciences*, 2013, Vol. 5 (2) 191-198
- [16]. Mardan MA, Mufti TS, Khattak IU, Chilkunda N, Alshayeb AA, Mohammad AM, urRehman Z. Role of ultrasound in acute appendicitis. *J Ayub Med Coll Abbottabad.* 2007 Jul-Sep;19(3):72-9
- [17]. D'Ippolito, Giselle GuedesNetto de Mello ,Jacob Szejnfeld. The value of unenhanced CT in the diagnosis of acute appendicitis. *Rev Paul Med* 1998;116(6):1838-45
- [18]. Wim T. Van Den Broek, Bart B. Bijnen, Bram Rijbroek and Dirk J. Gouma.. Scoring and diagnostic laparoscopy for suspected appendicitis. *European Journal of Surgery* September 2002; Volume 168, Issue 6:pages 349–354
- [19]. Subedi N, Dangol US, Adhikary MB, Pudasaini S, Baral R. Acute appendicitis: a 2- year review of clinical presentation and histopathology. *Journal of Pathology of Nepal* (2011); Vol. :104 -107